

Taylor & Francis
Taylor & Francis Group

Physiotherapy Theory and Practice
An International Journal of Physical Therapy

ISSN: (Print) (Online) Journal homepage: https://www.tandfonline.com/loi/iptp20

Efficacy of immediate physiotherapy after surgical release of zygomatico-coronoid ankylosis in a young child: A case report

Krzysztof Dowgierd, Anna Lipowicz, Małgorzata Kulesa-Mrowiecka, Wojciech Wolański, Paweł Linek & Andrzej Myśliwiec

To cite this article: Krzysztof Dowgierd, Anna Lipowicz, Małgorzata Kulesa-Mrowiecka, Wojciech Wolański, Paweł Linek & Andrzej Myśliwiec (2021): Efficacy of immediate physiotherapy after surgical release of zygomatico-coronoid ankylosis in a young child: A case report, Physiotherapy Theory and Practice, DOI: 10.1080/09593985.2021.1952672

To link to this article: https://doi.org/10.1080/09593985.2021.1952672

Published online: 15 Jul 2021.

PHYSIOTHERAPY THEORY AND PRACTICE
https://doi.org/10.1080/09593985.2021.1952672

Taylor & Francis
Taylor & Francis Group

Efficacy of immediate physiotherapy after surgical release of zygomatico-coronoid ankylosis in a young child: A case report

Krzysztof Dowgierd[a], Anna Lipowicz[b], Małgorzata Kulesa-Mrowiecka[c], Wojciech Wolański[d], Paweł Linek[e], and Andrzej Myśliwiec[f,g]

[a]Department of Clinical Pediatrics, Regional Specialized Children's Hospital, Head and Neck Surgery Clinic for Children and Young Adults, University of Warmia and Mazury, Olsztyn, Poland; [b]Department of Anthropology, Institute of Environmental Biology, Wroclaw University of Environmental and Life Sciences, Poland; [c]Department of Physiotherapy, Institute of Physiotherapy, Faculty of Health Sciences, Jagiellonian University, Medical College, Cracow, Poland; [d]Department of Biomechatronics, Faculty of Biomedical Engineering, Silesian University of Technology, Zabrze, Poland; [e]Musculoskeletal Elastography and Ultrasonography Laboratory, Institute of Physiotherapy and Health Sciences, Academy of Physical Education, Katowice, Poland; [f]Laboratory of Physiotherapy and Physioprevention, Institute of Physiotherapy and Health Science, Academy of Physical Education, Katowice, Poland; [g]Specialized Physiotherapy Center, Rybnik, Poland

ABSTRACT

Background: Temporomandibular joint ankylosis (TMJ ankylosis) manifests itself as a locked jaw and reduced mouth opening. We hypothesized that the efficacy of TMJ ankylosis surgery in a child may largely depend on physiotherapeutic management.

Case Description: : In this case report, we present the treatment of a girl between 1 and 4 years of age, who was unable to open her jaws immediately after birth. Congenital ankylosis was diagnosed.

Intervention: : Two models of therapeutic management were presented, with a surgical procedure to release bone fusion adopted as a starting point. In the first model, the rehabilitation procedure started 21 days after surgery.

Outcomes: : Despite rehabilitation, no clinical improvement was achieved (i.e. the child was still unable to open her jaws). In the second model, rehabilitation started from the day after surgery and management according to the second model allowed for obtaining therapeutic benefits. After therapy, the girl was able to abduct the mandible to a degree allowing for improved speech and the ability to crush food.

Conclusions: : This clinical case shows that the efficacy of surgical procedures may depend on the type of postoperative management. It was demonstrated that physiotherapy started immediately after the procedure to release the ankylosis improved the mandible mobility outcomes for this child.

ARTICLE HISTORY
Received 7 June 2020
Revised 2 March 2021
Accepted 5 June 2021

KEYWORDS
Temporomandibular joint; ankylosis; physical therapy; surgery

INTRODUCTION

Temporomandibular joint (TMJ) ankylosis may only affect the extra-particular area or be of a complex nature. An example of pseudo-ankylosis is zygomatico-coronoid ankylosis (Kallalli, Rawson, Manugutti, and Sulaga, 2014). The human disease database Malacards includes TMJ ankylosis in the group of rare diseases.

TMJ ankylosis is manifested by the restriction of mouth opening, sometimes accompanied by pain and problems with the respiratory and digestive systems. In TMJ ankylosis, crushing, chewing, and swallowing foods is often difficult and increases the risk of choking. The limitation in mouth opening impairs oral hygiene, increasing the risk of caries, periodontal diseases, facial skeleton growth disorders, and speech disorders (Gil-Da-Silva-Lopes and Luquetti, 2005; Kumar, Fernandes, and Sandhu, 2018; Ulański, Dowgierd, and Kozakiewicz, 2014; Yano, Taniguchi, and Tsuneyoshi, 2017).

A varied approach to the treatment of TMJ ankyloses has been used in the literature. This approach depends on the location of ankylosis, severity, the patient's age, and postoperative complications (Dhupar, Akkara, Khandelwal, and Louis, 2018; Kaban, Bouchard, and Troulis, 2009). Some authors have emphasized the importance of physiotherapy in the postoperative treatment of TMJ ankyloses, but this has not been fully described (Dhupar, Akkara, Khandelwal, and Louis, 2018; Kaban, Bouchard, and Troulis, 2009). Due to the low prevalence of TMJ ankylosis, there is an absence of developed recommendations concerning physiotherapeutic procedures in children and adults. Dhupar, Akkara, Khandelwal, and Louis (2018) indicated that the effectiveness of TMJ ankylosis surgery depends on

CONTACT Paweł Linek Musculoskeletal Elastography and Ultrasonography Laboratory, Institute of Physiotherapy and Health Sciences, the Jerzy Kukuczka Academy of Physical Education, 40-065, Mikolowska 72a Katowice, Poland linek.fizjoterapia@vp.pl

intensive physiotherapy implemented immediately after surgery. Therefore, the aim of this case report was to present the efficacy of two models of post-surgical management (delayed vs. immediate) performed in the same child after successive surgeries to release zygomatico-coronoid ankylosis.

CASE DESCRIPTION

Patient

This report presents the physiotherapy intervention and outcomes of the treatment of a female child between 1 and 4 years of age, born in the Silesian region of Poland. The child was born from a second pregnancy, and based on the number of erupted teeth (dental age estimation), child development was classified as typical. No history of bone defects was reported in the parents or in close relatives. Immediately after birth, the pediatrician diagnosed the child's oral cavity disorders, consisting of the inability to open the jaws, and referred the girl to an orthodontist for consultation. The first diagnosis was made 5 days after birth by a specialist in the field of craniofacial defects with many years of experience, who diagnosed the child with hemifacial microsomia. From the functional standpoint, a limited mandibular depression and a right occlusal fissure larger than the left one was observed. An active suction reflex was also found, but with no tongue extension between the upper and lower alveolar ridges. The lower part of the left ear lobe was smaller than that on the right. The child was referred to an extended specialist consultation in the Center for Facial Craniofacial Defects and Maxillofacial Surgery in Olsztyn, Poland. At age 16 months, a computed tomography (CT) scan was obtained to diagnose congenital TMJ ankylosis. The girl was qualified for surgery to release the function of the left TMJ joint.

First Surgical Intervention

At the age of 19 months, surgery was performed from an internal access. After cutting the mucosa of the oral vestibule on the ankylosis side, the jawbone was accessed, and then the coronoid process of the mandible was exposed, together with the zygomatic bone shaft. The main cause for the restriction of joint mobility was determined during the detailed intraoperative analysis of the surgical field. Fusion of the coronoid process with the zygomatic arch was found. An osteotomy was performed to remove the bone fusion between the zygomatic bone shaft and coronoid process of the mandible. This procedure allowed for obtaining a correct opening without the need to introduce interpositional material. Intraoperative the surgeon was able to passively open the jaw up to 30 mm.

First Postoperative Physiotherapy Care

The first stage of physiotherapy began on day 21 after surgery at the Specialized Physiotherapy Center in the Silesian region of Poland; physiotherapy continued for 18 months. The duration of each therapeutic session was 30 minutes. The protocol was as follows: 1) 5 minutes of masseter muscle massage from the oral cavity side (Figure 1A) as well as relaxation and stretching techniques from the cheek side (Figure 1B); 2) 15 minutes of

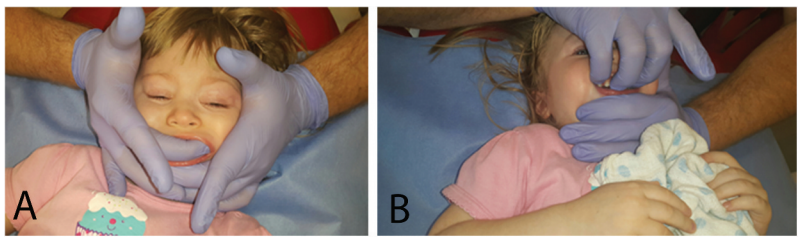

Figure 1. Masseter muscle massage from the oral cavity side (A) and relaxation/stretching techniques from the cheek side (B).

Figure 2. The jaw opening technique using wooden laryngological spatulas.

Figure 3. Temporomandibular joint mobilization and relaxation techniques.

the main therapy, in which wooden laryngological spatulas were used in order to generate jaws opening forces (Figure 2) (Lee et al., 2018); and 3) 10 minutes of TMJ mobilization and relaxation techniques (Figure 3).

The therapy was performed once a day at the physiotherapy center. The main therapy (i.e. generating the jaws opening forces) was also administered by parents at home (15 minutes of therapy applied every 2 hours, also at night). Parents were instructed to put their fingers or a spatula between the child's teeth and force jaw opening movements.

Second Surgical Intervention

A second surgical bone fusion release procedure at age 37 months was performed in the same hospital where the first surgery was performed and was performed by the same maxillary surgeon. Before the procedure, a CT scan was obtained again, during which the recurrence of fusion of the coronoid process with the zygomatic arch and massive scarring was diagnosed on the same side of the mandible. A re-ankylotic fibro-osseous block connecting the hypoplastic shaft and ramus of the mandible with the zygomatic arch in the location of the previous scar limiting the jaw opening to 3 mm was reached using the intraoral access under general anesthesia. Then, using surgical chisels and a saw, a piece of the ankylotic block (part of the mandibular shank) was cut out to release the mandible and to allow the jaw to open up to about 30 mm. Due to the close location of the 37 tooth bud in the area of ankylosis, the decision was made to extract it. The osteotomy of a larger area of the apical part of the coronoid process was performed to such a degree that the risk of recurrence of bone fusion was minimized. After an analysis of the changes that had occurred since the previous surgery and due to insignificant damage to the joint, the surgeon decided to leave the head of the mandible.

Second Postoperative Physiotherapy Care

The second stage of physiotherapy began on the day after surgery in the hospital where the surgery was performed. On the fifth day, the child was discharged and transferred to the Specialized Physiotherapy Center, the same center and the same physiotherapist as after the first surgery in the Silesian region of Poland for further physiotherapy. The physiotherapy continued for 12 months and the duration of each therapeutic session was 30 minutes. The protocol was as follows: 1) 5 minutes of masseter muscle massage from the oral cavity side (Figure 1A) as well as relaxation and stretching techniques from the cheek side (Figure 1B); 2) 15 minutes of the main therapy with the use silicone wedges (20 mm wide and 35 mm high) instead of wooden laryngological spatulas in order to generate jaw opening forces in a higher range (Figure 4 and Figure 3) 10 minutes of TMJ mobilization and relaxation techniques (Figure 3).

For the first week after the second surgery, the child received 1 mg Nalpain (Nalbuphine) and a 125 mg Nurofen (Ibuprofen) suppository 30 minutes before the physiotherapy procedure was administered. After the use of analgesics, physiotherapy was carried out twice a day in the outpatient setting and every 2 hours at home. From the second week after surgery, the use of analgesics was not needed. Physiotherapy continued to be carried out once a day in the outpatient setting and

Figure 4. The jaw opening technique using silicone wedges.

every 2 hours at home. After each physiotherapy session, the girl held wedges between her teeth for about 1 hour. Due to the presence of postoperative wounds, for the first two weeks, physiotherapy procedures were performed using sterile surgical gloves.

The child's parents were instructed on how to perform everyday exercises in sets with breaks of a maximum of 2 hours. The home therapy consisted of 1) relaxation of the external tissues with a warm gel or massage; and 2) opening the mouth and inserting the silicone wedge to stabilize the therapeutic effect for about 1 hour. During the night, the therapy only included opening the mouth and inserting the wedge for 1 hour. A detailed scheme of the treatment during the first 4 years of life is shown on Figure 5.

Outcome Measurements

Due to the mobility observed only for the mandibular abduction movement (a maximal interincisal opening), all measurements were taken with a millimeter ruler between the incisal edges of the upper and lower incisors in the center line, with the maximum mandible abduction. The interincisal opening measurements were systematically taken by a physiotherapist at the beginning of each therapy week with use the same measurement tool.

OUTCOMES

First Surgical Intervention and Physiotherapy Care

Before the first surgery, the maximal interincisal opening was 1 mm and intraoperatively easily reached up to 30 mm. The first stage of physiotherapy started 21 days after surgery with 1 mm of maximal interincisal opening without any lateral or protrusive mandibular movements. During the first three months of physiotherapy, the maximal interincisal opening increased from 1 mm to 4 mm (1 mm of visible improvement per month). During the next months of physiotherapy, there was no further improvement, and the maximal interincisal opening mandible abduction was still 4 mm and no protrusion or laterotrusion movement was found. The

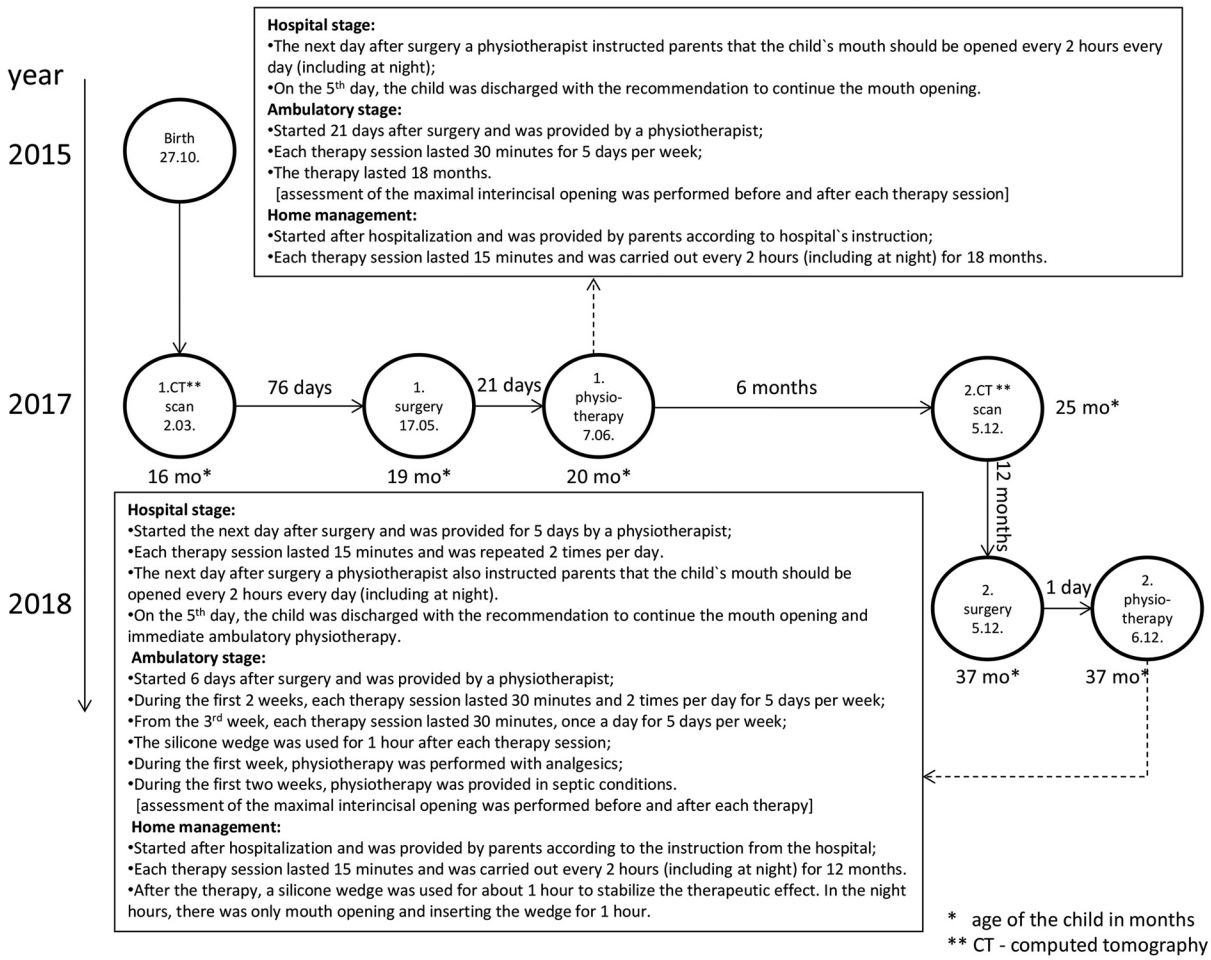

Figure 5. A detailed scheme of the treatment during the first 4 years of life.

tongue did not extend beyond the line of the teeth and it was impossible to serve chopped food, and nutrition was delivered in a semi-liquid state. Taking into account a lack of significant improvement, the physiotherapy was continued, but a decision to undergo another surgery was undertaken.

Second Surgical Intervention and Physiotherapy Care

Before the second surgery, the maximal interincisal opening was 4 mm and, intraoperatively, it easily reached up to 30 mm. The second stage of physiotherapy started after surgery with a maximal interincisal mandible opening of 25 mm. As the tissues healed, the range of the maximal interincisal opening began to gradually decrease and reach 16 mm 3 months after the second surgery. The physiotherapy applied during the next 9 months did not change the range of the maximal interincisal opening. Thus, the range of jaw mobility was up to 16 mm 12 months after the second surgery. During the physiotherapy period, the girl learned new skills: pushing her tongue beyond the line of her teeth and eating chopped food (including meat and bread) on her own. The protrusion was still not achieved. Laterotrusion remained only traceable. The difference in mandibular abduction on the first day of physiotherapy and in the final phase of treatment in the second phase is presented in Figure 6.

Although, the maximal interincisal opening was stabilized at the level of 16 mm without any improvement during the 12 months of physiotherapy, the maximal interincisal opening was sufficient to learn some functional activities. During the second postoperative treatment, the child started to eat all types of food (larger pieces of meat had to be cut into smaller ones). The child developed an individual linear mechanism for food grinding in the mouth and started to speak according to her age and sing songs. Quality of sleep improved and respiratory problems disappeared.

Figure 6. The difference in jaw opening on the first day of physiotherapy and in the final phase of treatment.

DISCUSSION

The aim of this case report was to present two different models of rehabilitation (deferred vs. immediate) after two surgeries to release TMJ ankylosis. After the first surgery, the physiotherapy started 21 days later due to the wound and pain. After the second surgery, the physiotherapy started immediately (on the next day) with use of analgesics and maintaining septic conditions. On day 21 after the first surgery, the physiotherapist who started the treatment was able to obtain a maximal interincisal opening of 1 mm. Thus, 29 mm of maximal interincisal opening had been lost as the intraoperative maximal interincisal opening was up to 30 mm. During the first three months of physiotherapy after the first surgery, the maximal interincisal opening was 4 mm. During the next fifteen months of physiotherapy, there was no more improvement (still 4 mm). Similarly, on the next day after the second surgery, the same physiotherapist was able to get a maximal interincisal opening of 25 mm. Thus, the only 5 mm of maximal interincisal opening had been lost as the intraoperative maximal interincisal opening was also 30 mm. During the first three months of physiotherapy after the second surgery, the maximal interincisal opening systematically deteriorated and stabilized at 16 mm.

Based on the post-surgery results, we hypothesize that the postponement in physiotherapy after the first surgery may have been a major variable affecting the maximal interincisal opening. In both surgeries, the maximal interincisal opening of 30 mm was intraoperatively easy obtained. Thus, it can be assumed that, immediately after surgery, the mandibular abduction movement was similar and both surgeries were performed properly. Kaban, Bouchard, and Troulis (2009) have claimed that, with correctly performed surgery, the intraoperative value of the maximal interincisal opening should be easily obtained. In our case report, both surgeries easily allowed 30 mm of maximal interincisal opening during the procedure. The reason for the substantial reduction in the maximal interincisal opening was likely not caused by the surgery itself. The probable reasons for the substantial reduction in the maximal interincisal opening after first surgery were: 1) the tissue healing process occurred or even finished before the child started physiotherapy, thereby initiating process of re-ankylosis; and 2) a loss of flexibility in the postoperative

scar. Despite postoperative symptoms such as pain in the operated region, swelling and bleeding after the surgery, early physiotherapy was implemented after the second surgery. The second treatment model did not result in an increase in the maximal interincisal opening, but it allowed for maintaining function to facilitate the improvement of speech and food intake and crushing. This was not achieved during the first (deferred) physiotherapy procedure. The findings of this case report support Al-Hudaid et al. (2017) observation that re-ankylosis may be due to a lack of adequate physiotherapy.

After the second surgery, the physiotherapy started the day after surgery, which gave the physiotherapist better options to work (i.e. greater range of movement) as the flexibility of the operated area had not decreased so much yet; moreover, the tissue healing process had just begun and there was no scar yet. It is possible that tissue stimulation during the early period (first 2 weeks) after the second surgery allowed more tissue flexibility and ensured a better blood supply to the operated area. In the process of tissue healing, the inflammatory phase lasting about two days and the proliferation phase lasting up to two weeks after the procedure are crucial. During this period (the first two weeks), systematic treatment (i.e. physiotherapy) including tissue relaxation techniques and movement is important, as it allows for maintaining the flexibility of tissues, improves the blood supply to tissues, and optimizes the healing and revascularization process (McKinley, 2003; Menke et al., 2007). Menke et al. (2007) had suggested that the greatest effects of tissue healing can be obtained in the inflammatory and proliferative phases, lasting up to about two weeks after surgery. Mechanical, biochemical, and morphological changes within the tissues occur as a result of joint immobilization, as seen after the first surgery. Some studies have shown that, during immobilization, the thickness of articular cartilage decreases; softening of the articular cartilage is an indication of a loss of flexibility and increased vulnerability to distortion (Vanwanseele, Lucchinetti, and Stüssi, 2002; Vincent and Wann, 2019). It was also indicated that chondrocytes may respond to changes induced by decreased active and passive mechanical stress, and remodel their surrounding extracellular matrix with a lower concentration of components of the extracellular matrix (i.e. collagen fibers, proteoglycans, and hyaluronic acid) (Lee et al., 2010; Vanwanseele, Lucchinetti, and Stüssi, 2002). As a consequence of the deterioration in cartilage metabolism, stiffness and reduced elasticity of tissues is observed (Lee et al., 2010). Dhupar, Akkara, Khandelwal, and Louis (2018) showed that immediate physiotherapy undertaken on the first day after TMJ ankylosis release was more effective in adults. Commander et al. (2016) also suggested that physiotherapy is necessary in the area of the new scar to avoid hypertrophy and provide elasticity to the tissue through stimulation of collagen and elastic fiber production. This may at least partially explain the reason why physiotherapy treatment implemented shortly after the second surgery led to a much better treatment result in that the interincisal opening enabled basic function of the jaw.

This study has also shown that effective physiotherapy can be started in a three-year-old child. In the case discussed in the study, restrictions resulting from the lack of mandible movement may threaten the health and life of the child by increasing the risk of choking (Yano, Taniguchi, and Tsuneyoshi, 2017), tooth caries and periodontal diseases (Kumar, Fernandes, and Sandhu, 2018), malnutrition and disorders of growth processes, or facial deformities (Gil-Da-Silva-Lopes and Luquetti, 2005; Ulański, Dowgierd, and Kozakiewicz, 2014). To our knowledge, no other studies have evaluated the potential effect of immediate physiotherapy in very young children.

The present report has a number of limitations. First, the second surgery was not the same as the first one. During the second surgery, the re-ankylosed bone mass had to be more radically extracted as compared to the first surgery. This might have affected the patient's maximal interincisal opening during the next few months of physiotherapy. However, the surgeon was able to easily open the jaw up to 30 mm during both surgical procedures. This means that the ability to open the jaw was similar after both surgeries. It seems important that, 21 days after the first surgery, the child was admitted to physiotherapy with a maximal interincisal opening of 1 mm (as it was before the first surgery). After the second surgery, the child started physiotherapy on the next day with a reduction in the maximal interincisal opening of only 5 mm. It seems warranted to claim that the postponement of the physiotherapy by 20 days after the first surgery may be the major variable affecting the surgery results (huge reduction in the maximal interincisal opening). Second, during the child's care, we were unable to control for numerous variables like age and developmental stage that may have changed in the interval between the first and second surgeries; the time between the first and the second surgery was 18 months. The first surgery was at the age of 19 months and the second surgery was at the age of 37 months. During this time span, many changes occurred in the facial and mandible area (e.g. increased dimensions, deciduous tooth eruption,

partial mandibular bone remodeling) (Liu, Behrents, and Buschang, 2010) and new functional and mechanical demands occurred (Grunheid et al., 2009). All of these factors might have affected the outcomes results. However, changes with age seem to have a small impact on the progress of treatment, as the greatest growth rates occur between four and twelve months of age; subsequently, the mandible displays decelerating rates of growth (Liu, Behrents, and Buschang, 2010). Third, only one parameter (i.e. maximal interincisal opening) was quantitatively measured in this case report. However, our observation over a period of several months did not show that the mandible could be effectively moved in other directions. Fourth, after the second surgery, the child was also able to change her eating behavior (from soft to more solid products), thereby affecting tongue movement and pressure on the maxilla and mandible (Fujita and Maki, 2018). This may have affected our findings.

Conclusion

Postoperative procedures and the time of initiating physiotherapy may determine the efficacy of surgical procedures. Physiotherapy implemented immediately after surgery to release congenital TMJ ankylosis (zygomatico-coronoid ankylosis) may help to maintain the mobility of the mandible, allowing for important biomechanical and physiological functions. This clinical case demonstrates that effective physiotherapeutic management was effectively implemented for a three-year-old child after congenital zygomatic-coronoid ankylosis release.

Disclosure statement

The authors declare no conflict of interest.

ORCID

Krzysztof Dowgierd http://orcid.org/0000-0002-7605-2080
Paweł Linek http://orcid.org/0000-0002-8542-8123

References

Al-Hudaid A, Aldialami A, Helmi J, Al-Wesabi M, Madfa A 2017 Management of temporomandibular joint ankylosis in Yemeni children by metatarsal bone grafts. Journal of Oral Research 6:216–221 10.17126/joralres.2017.060

Commander SJ, Chamata E, Cox J, Dickey RM, Lee EI 2016 Update on postsurgical scar management. Seminars in Plastic Surgery 30:122–128 10.1055/s-0036-1584824

Dhupar V, Akkara F, Khandelwal P, Louis A 2018 Zygomatico-coronoid ankylosis as sequel of inadequate treatment. Annals of Maxillofacial Surgery 8:158–161 10.4103/ams.ams_107_15

Fujita Y, Maki K 2018 Association of feeding behavior with jaw bone metabolism and tongue pressure. Japanese Dental Science Review 54:174–182 10.1016/j.jdsr.2018.05.001

Gil-Da-Silva-Lopes VL, Luquetti DV 2005 Congenital temporomandibular joint ankylosis: Clinical characterization and natural history of four unrelated affected individuals. Cleft Palate-Craniofacial Journal 42:694–698 10.1597/04-027.1

Grunheid T, Langenbach GE, Korfage J, Zentner A, Van Eijden TM 2009 The adaptive response of jaw muscles to varying functional demands. European Journal of Orthodontics 31:596–612 10.1093/ejo/cjp093

Kaban LB, Bouchard C, Troulis MJ 2009 A protocol for management of temporomandibular joint ankylosis in children. Journal of Oral and Maxillofacial Surgery 67:1966–1978 10.1016/j.joms.2009.03.071

Kallalli BN, Rawson K, Manugutti A, Sulaga S 2014 Right zygomatico-coronoid ankylosis: A rare clinical entity. Journal of Indian Academy of Oral Medicine and Radiology 26:323–326 10.4103/0972-1363.145019

Kumar B, Fernandes A, Sandhu PK 2018 Restricted mouth opening and its definitive management: A literature review. Indian Journal of Dental Research 29:217–224 10.4103/ijdr.IJDR_544_16

Lee R, Yeo ST, Rogers SN, Caress AL, Molassiotis A, Ryder D, Sanghera P, Lunt C, Scott B, Keeley P, et al. 2018 Randomised feasibility study to compare the use of Therabite® with wooden spatulas to relieve and prevent trismus in patients with cancer of the head and neck. British Journal of Oral and Maxillofacial Surgery 56: 283–291 10.1016/j.bjoms.2018.02.012

Lee S, Sakurai T, Ohsako M, Saura R, Hatta H, Atomi Y 2010 Tissue stiffness induced by prolonged immobilization of the rat knee joint and relevance of AGEs (pentosidine). Connective Tissue Research 51:467–477 10.3109/03008201003686941

Liu YP, Behrents RG, Buschang PH 2010 Mandibular growth, remodeling, and maturation during infancy and early childhood. Angle Orthodontist 80:97–105 10.2319/020309-67.1

McKinley T 2003 Principles of fracture healing. Surgery 21: 209–212

Menke NB, Ward KR, Witten TM, Bonchev DG, Diegelmann RF 2007 Impaired wound healing. Clinics in Dermatology 25:19–25 10.1016/j.clindermatol.2006.12.005

Ulański ŁE, Dowgierd K, Kozakiewicz M 2014 Ankylosis of the temporomandibular joint and its surgical reconstruction - Case reports. Modern Methods of Treatment. Dental and Medical Problems 51: 519–530

Vanwanseele B, Lucchinetti E, Stüssi E 2002 The effects of immobilization on the characteristics of articular cartilage: Current concepts and future directions. Osteoarthritis and Cartilage 10:408–419 10.1053/joca.2002.0529

Vincent TL, Wann AK 2019 Mechanoadaptation: Articular cartilage through thick and thin. Journal of Physiology 597:1271–1281 10.1113/JP275451

Yano T, Taniguchi M, Tsuneyoshi I 2017 Food choking in a patient with congenital temporomandibular joint ankylosis. Turkish Journal of Anaesthesiology and Reanimation 45:380–381 10.5152/TJAR.2017.45143